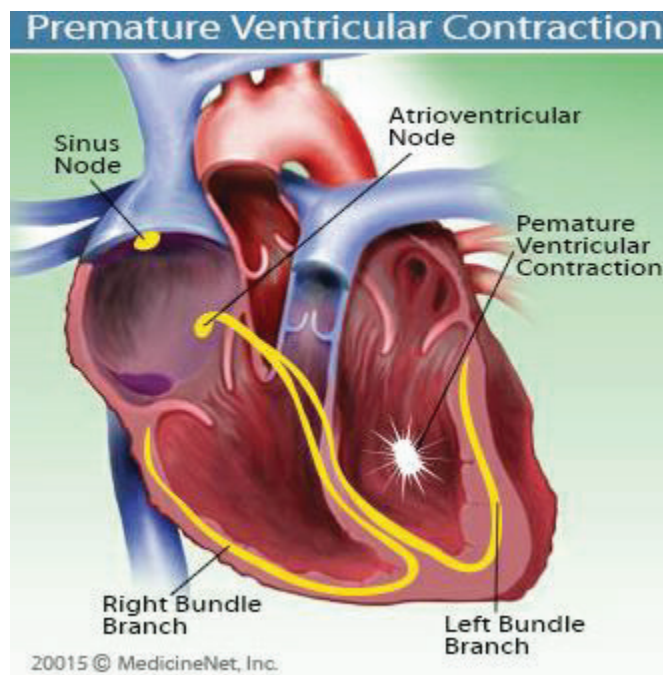


# PREMATURE VENTRICULAR CONTRACTIONS (PVC)

- Ventricular arrhythmias are abnormal heart rhythms that originate in the bottom chambers of the heart called the ventricles.
- Premature ventricular contraction (PVC) is a premature ectopic heartbeat (too-early heartbeat) that originates in the Purkinje fibers of the ventricle rather than the normal sinoatrial node and disrupts the heart's normal rhythm.
- The pattern is a normal beat, an extra beat (the PVC), a slight pause, then a stronger-than-normal beat. This pattern may occur randomly or at definite intervals.
- Palpitations are discomforting feelings due to forceful heartbeats. The heart fills with more blood during the pause following the PVC, giving the next beat extra force often felt in the chest and in the neck.
- Immediately after a premature ventricular contraction, the electrical system of the heart resets. This resetting causes a brief pause in heartbeat, and some patients report feeling the heart briefly stopping after a premature ventricular contraction.



## Who is at risk for PVCs?

- Almost everyone has PVCs at some time, from childhood through adulthood.
- In a study of healthy members of the military, the incidence of PVCs was 0.5% among those under the age of 20 and 2.2% in those over the age of 50. This study shows the rise in PVCs – as in all types of abnormal heart rhythms – that occurs with age.
- PVCs occur more commonly in older people and in individuals with underlying heart disease, including a history of heart attack and high blood pressure
- People with a family history of cardiac arrhythmias (abnormal heart rhythm) also have a higher risk for PVCs.
- PVCs can also occur in healthy hearts and may simply be a response to: increased catecholamines (adrenaline excess such as at times of stress), Substances like caffeine, cocaine, and alcohol, hypoxia (low amounts of oxygen in the blood), for example, hypoxia occurs with lung diseases

such as emphysema or chronic obstructive pulmonary disease (COPD); fever, prescription pills like tricyclic antidepressants, sympathomimetics, and digoxin, electrolyte disturbances hypokalemia (low blood levels of potassium), and hypomagnesaemia (low blood levels of magnesium) hypokalemia and hypomagnesaemia can occur, for example, in patients taking diuretics (water pills), sleep deprivation, physical exertion or exhaustion

- They may also be indicative of, cardiomyopathy, valvular disease, atherosclerosis, endocarditis.
- PVCs can predispose to serious arrhythmias if they occur in association with a heart attack or during cardiomyopathy.

### What causes PVCs?

- Healthy people of any age can experience PVCs.
- In most cases of occasional PVCs the underlying cause cannot be identified.
- PVCs that occur frequently or for longer periods of time are more likely to be related to heart disease, an injury to the heart or other, non-cardiac conditions such as a chemical imbalance in the body.
- Certain medications, alcohol, illegal drugs and high levels of adrenaline due to stress, exercise or caffeine also can cause PVCs.

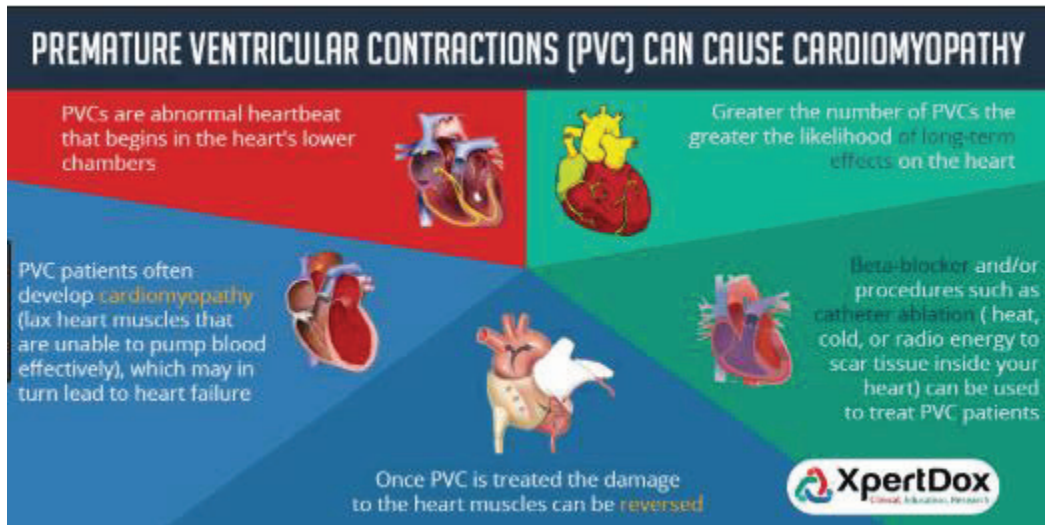
### What are the symptoms of PVCs?

- When a PVC occurs as a single premature beat, patients may describe the feeling as a "palpitation" or "skipped beat."
- The beat following the PVC can be strong enough to cause pain or discomfort in the chest.
- Individuals who have frequent PVCs or a series of them may experience a fluttering sensation in the chest or neck or shortness of breath
- If PVCs are frequent enough to reduce the heart's pumping ability, the individual may experience weakness, dizziness or fainting. This is because frequent premature ventricular contractions can diminish the ability of the heart to pump blood to the other organs (diminished cardiac output), resulting in low blood pressure.

### What are the risks associated with PVCs?

- Most PVCs occur infrequently and are benign.

- Frequent PVCs may increase the risk of developing other, more serious cardiac arrhythmias.
- Individuals with frequent PVCs who have underlying heart disease, structural abnormalities in the heart or have had a previous heart attack have a higher risk of death.
- Over time, frequent PVCs can, in some patients, cause changes in the heart function (cardiomyopathy- weakening of the heart muscle)



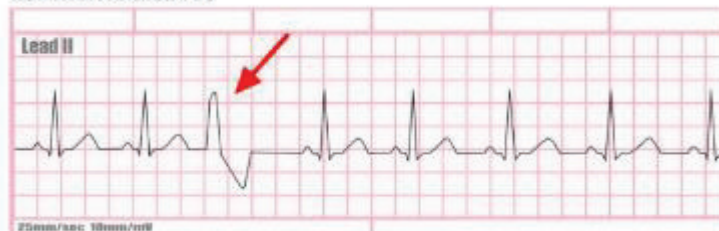#### How are PVCs diagnosed?

- PVCs can be difficult to diagnose because they occur at unpredictable intervals.
- In most cases, PVCs are difficult to detect during a routine physical unless you have one during the exam or have other signs of structural heart problems.
- In individuals without any known heart disease, PVCs often are discovered incidentally during a routine electrocardiogram (EKG)
- In patients with known heart disease, PVCs may be detected during other diagnostic testing for that condition.
- A patient with symptoms of PVCs who consults a heart specialist will undergo an ECG, the standard test for diagnosing PVCs. It is relatively inexpensive, non-invasive and accurate.

#### EKG and PVC

- An electrocardiogram (EKG or ECG) is a brief recording of the heart's electrical discharges
- On an EKG: PVC's are characterized by premature and bizarrely shaped QRS complexes that are unusually long (typically >120 msec) and appear wide on the electrocardiogram (ECG). These complexes are not preceded by a P wave, and the T wave is usually large and oriented in a direction opposite the major deflection of the QRS.

NSR with isolated PVC





- Patients with three or more consecutive premature ventricular contractions in a row have ventricular tachycardia

### TYPES OF PVCs

**Infrequent PVCs:** Less than five PVCs/min.

**Frequent PVCs:** Five or more PVCs/min.

**Isolated PVCs (Beats):** PVCs occurring singly.

**Group Beats, Bursts, Salvos:** PVCs occurring in groups of two or more.

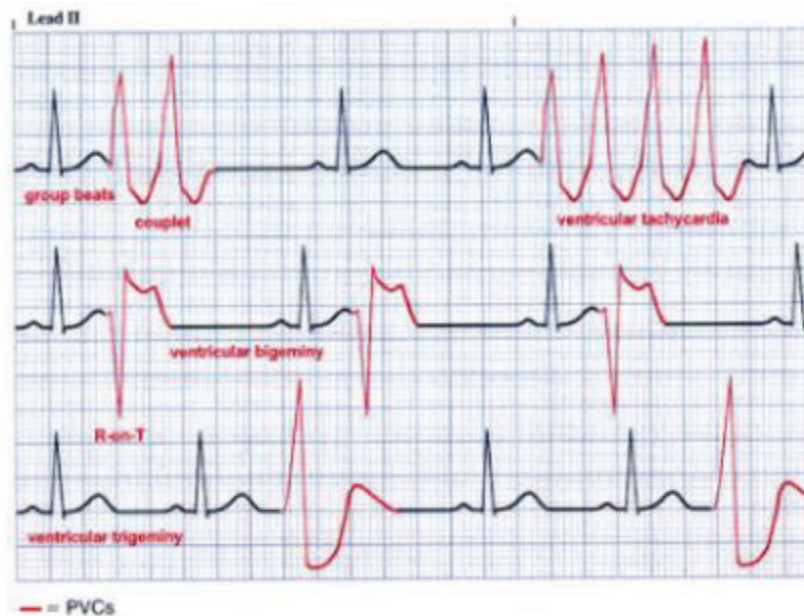
**Paired PVCs (Couplet):** Two PVCs in a row.

**Ventricular Tachycardia:** Three or more PVCs in a row.

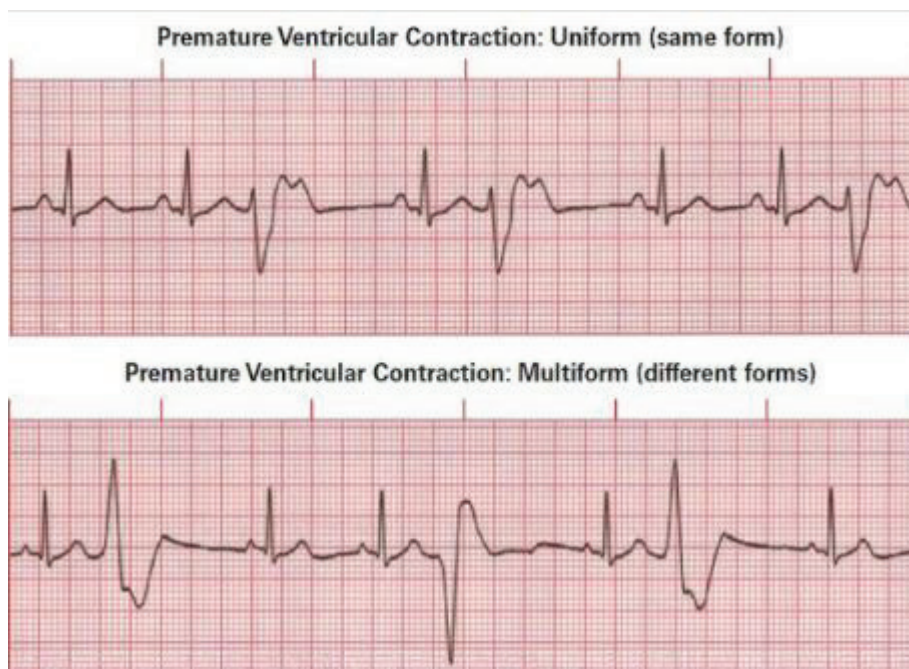
**Ventricular Bigeminy:** PVCs alternating with the QRS complexes of the underlying rhythm.

**Ventricular Trigeminy/Ventricular Quadrigeminy:** PVCs following every two or three QRS complexes of the underlying rhythm, respectively.

**R-on-T Phenomenon:** A PVC occurring during the downslope of the preceding T wave (vulnerable period of ventricular repolarization).



I look at the PVC to determine morphology (shape) so I may better treat you as some PVC's morphologies are known to be benign and can be are sensitive to either certain medications (such as B-blockers or calcium channel blockers) or catheter ablation procedures



### **PVC's and Cardiac Monitoring**

- Even if you have no symptoms or only minimal symptoms, patients with a high PVC burden require follow-up because of the association between frequent PVCs and arrhythmia-induced cardiomyopathy (weakening of the heart)
- What constitutes a “high” PVC burden remains a matter of debate. Left ventricular dysfunction has generally been reported at PVC burdens above 15% to 25% of the total cardiac beats, though this percentage can be as low as 10%.
- A Holter monitor, a portable ECG that provides 24 or 48 hours of continuous recording, may be used for patients who experience PVCs at least once a day.
- The information from a Holter monitor is very useful in determining the frequency of PVCs and correlating symptoms such as faintness or dizziness with the arrhythmia.

### **PVC and Echocardiogram**

- Echocardiography uses ultrasound waves to produce images of the heart's chambers and valves and the lining around the heart (pericardium).
- Echocardiography is useful in measuring the size of the heart chambers, the forcefulness of heart ventricle contractions, the thickness of the heart muscles, and the functioning of the heart valves.
- Echocardiography is therefore useful in diagnosing conditions that can cause premature ventricular contractions such as:
  - Mitral valve prolapse: Echocardiography can detect and measure the severity of mitral valve prolapse and other valvular diseases.
  - Muscle hypertrophy: Echocardiography can detect heart muscle hypertrophy (thickening of heart muscle) as a result of long-term high blood pressure.
  - Heart muscle damage: Echocardiography can measure the extent of heart muscle damage from heart attacks or cardiomyopathy.
  - Ejection fraction: Echocardiography can be used to calculate the ejection fraction of the left ventricle.
    - Ejection fraction is a measure (estimate) of the amount of blood pumped during each contraction of the ventricle.
    - Heart ventricles extensively weakened by heart attacks or cardiomyopathy will have low ejection fractions.
    - Patients with low ejection fractions have higher risks of developing life-threatening ventricular tachycardias and fibrillations than patients with normal ejection fractions
    - What's normal? A normal heart's ejection fraction may be between 50% and 70%. What's too low? A measurement under 40% may be evidence of heart failure or cardiomyopathy.

### **Other Testing**

The American College of Cardiology recommends exercise testing for patients who experience PVCs with exercise or for whom an evaluation for coronary artery disease is indicated. During the test your electrocardiogram (EKG), heart rate, heart rhythm, and blood pressure are continuously monitored. If a coronary arterial blockage results in decreased blood flow to a part of the heart during exercise, certain changes may be observed in the EKG, including increases in premature ventricular contractions and development of ventricular tachycardias. The expected finding would be an increase in PVCs or ventricular tachycardia with exercise or in the subsequent recovery period. Exercise testing can be

combined with either echocardiographic or nuclear perfusion imaging to evaluate the possibility of myocardial ischemia. For patients unable to exercise, pharmacologic stress testing with dobutamine or a vasodilator agent can be performed.

Additionally, Advanced noninvasive cardiac imaging— such as computed tomography, magnetic resonance imaging, or positron-emission tomography— are reserved for specific clinical indications such as congenital heart disease, suspected cardiac sarcoidosis, and infiltrative heart disease, and for specific cardiomyopathies, such as hypertrophic cardiomyopathy and arrhythmogenic right ventricular cardiomyopathy. For example, frequent PVCs with a left bundle branch block morphology and superior axis raise the concern for a right ventricular disorder and may prompt me to order cardiac magnetic resonance imaging for either arrhythmogenic right ventricular cardiomyopathy or sarcoidosis.

### **How are PVCs treated?**

The reasons for treating premature ventricular contractions are: to relieve symptoms of palpitations; to treat conditions that cause premature ventricular contractions since many conditions that cause premature ventricular contractions are potentially life threatening; and to prevent ventricular tachycardia and sudden death

- For individuals who experience occasional PVCs with no other symptoms and no underlying heart disease or structural problems, no treatment is necessary.
- Lifestyle changes: You can help control your PVCs by reducing or eliminating your caffeine, tobacco and alcohol intake and reducing stress and anxiety. Stop the use of over-the-counter (OTC) nasal decongestants that may contain adrenaline such as medications containing pseudoephedrine.
- If medication you take routinely is causing your PVCs, we will discuss a possible change in medication
- When PVCs are due to some form of heart disease or structural abnormality, treating that problem often causes the PVCs to go away.
- Medications: Beta blockers — which are often used to treat high blood pressure and heart disease — can suppress premature contractions. Other medications, such as calcium channel blockers, or anti-arrhythmic drugs, such as amiodarone (Pacerone) or flecainide (Tambocor), also might be used if you have ventricular tachycardia or frequent PVCs that interfere with your heart's function.
- Radiofrequency catheter ablation. For PVCs that don't respond to lifestyle changes or medications, I may recommend ablation therapy. This procedure uses radiofrequency energy to destroy the area of heart tissue that is causing your irregular contractions.

### **Ablation for PVC's**

- Ablation is another treatment option for some patients with frequent or prolonged PVCs.
- In ablation therapy, radiofrequency waves are used to vaporize tiny amounts of tissue in the area of the heart where the extra beat originates.
- This is a minimally invasive procedure that is reserved for patients who cannot tolerate beta blockers, in whom medication is ineffective or who cannot comply with long-term drug therapy.
- PVCs can potentially be cured by catheter ablation when present at a sufficient burden to allow for activation mapping in the electrophysiology laboratory. The threshold for offering ablation varies, but is generally around 10% or greater
- Ablation can reverse the ventricular dysfunction and cardiomyopathy associated with frequent premature ventricular contractions.

- The ventricular function takes approximately 4 months to return to normal. Patients with premature ventricular contraction-mediated cardiomyopathy experience a marked improvement in quality of life following ablation therapy.

**CATHETER ABLATION FOR PREMATURE VENTRICULAR CONTRACTIONS**

"Benign" PVCs may actually impair the pumping efficiency of the heart and are associated with increased mortality and risk of sudden death

Ablation therapy is very successful in suppressing PVCs, with a success rate of almost 80%

Ablation can reverse the ventricular dysfunction associated with frequent PVCs in about 4 months' time

Ablation is an invasive procedure, complications such as bruising, bleeding or infection may arise after the procedure

XpertDox

### Premature Ventricular Contractions (PVC) Ablation When Is Catheter Ablation an Appropriate Treatment?

There are a large variety of ablations available to patients with heart rhythm disorders (catheter, surgical or alternative techniques)

- Catheter ablation is a minimally invasive, non-surgical procedure that is performed by an electrophysiologist (EP) like me, an electrician for your heart.
- Catheter ablation is an excellent choice for patients when medications are not effective, tolerated, or preferred.
- The goal of PVC ablation is to stop the incorrect electrical signals and restore a normal heart rhythm.
- Inside the heart (endocardial ablation) If your abnormal heartbeat is coming from inside your heart, special catheters are used to transmit electrical energy (radiofrequency ablation) or extreme cold (cryoablation) to the target area, damaging the tissue and causing scarring, blocking the electrical signals that are contributing to your PVC's
- I have extensive experience with radiofrequency (RF) which is currently my preferred method of ablation.
- When the PVC focus is identified, radiofrequency energy is applied to a small area (4 to 5 mm in diameter) to destroy the abnormal tissue.
- The number of burns required to treat the PVC varies among patients.
- Outside the heart (epicardial ablation). If your abnormal heartbeat is being caused by tissue on the outside of your heart, it is possible to use a long needle to access your heart. The needle is inserted through the skin on your chest and advanced through the lining of the fluid-filled sack (pericardium) that surrounds your heart. A hollow tube (sheath) is inserted and catheters are passed through the tube to access the outside surface of the heart. I do not perform this type of procedure and would refer you as needed if I felt this was the source of your PVC's

- Endocardial-Epicardial Sometimes a PVC ablation involves treatment inside the heart (Endocardial) and (Epicardial) outside the heart at the same time ). This is called a hybrid ablation.